

CLINICAL CASES



DOI: 10.5281/zenodo.11106983

UDC: 617.553-006.488-007.415-07-053.2

A CASE OF PHEOCHROMOCYTOMA ARISING FROM HETEROTOPIC ADRENAL GLAND IN CHILDREN

S. Babuci^{1,2}, V. Petrovici^{1,2}, I. Negru¹, I. Ambros^{1,2}, A. Berbeca¹, T. Pasicovchi^{1,2}, M. Malțev¹

¹ Public Medical Sanitary Institution Mother and Child Institute, National Scientific-Practical Center of Pediatric Surgery "Natalia Gheorghiu", Chișinău, Republic of Moldova

² State University of Medicine and Pharmacy "Nicolae Testemitanu", Chișinău, Republic of Moldova

Summary

Introduction. Pheochromocytoma is a catecholamine-secreting neuroendocrine tumor that originates in the chromaffin cells of the adrenal medulla or extra-adrenal sites, both derived from the embryonic neural crest. The term "pheochromocytoma" is reserved for tumors involving the adrenal glands, while for extra-adrenal tumors that come from the sympathetic and parasympathetic ganglia and have a noradrenergic phenotype, the term "paraganglioma" is used.

Case Report. Pheochromocytoma is a rare tumor in children. We present the case of a 9-year-old female child with heterotopic retroperitoneal localized pheochromocytoma, clinically manifesting hypertension, tachycardia and headache. The diagnosis was based on abdominal ultrasound, Computer tomography and contrast-enhanced Magnetic Resonance Imaging, confirmed by evaluation of free plasma catecholamine metabolites and testing of fractionated urinary metanephrines. This case is of interest due to an atypical position and vascularization of the pheochromocytoma, located retroperitoneally on the right, casuistically described in the literature, which created some diagnostic confusions.

Conclusion. The use of the transperitoneal approach, in this case, allowed an excellent exposure and radical removal of the tumor without injuring the kidney and ureter attached to the tumor.

Keywords: pheochromocytoma, heterotopy, hypertension, children

Introduction

Pheochromocytoma is a catecholamine-secreting neuroendocrine tumor that originates in the chromaffin cells of the adrenal medulla or extra-adrenal sites, both derived from the embryonic neural crest. The term "pheochromocytoma" is reserved for tumors involving the adrenal glands, while for extra-adrenal tumors that come from the sympathetic and parasympathetic ganglia and have a noradrenergic phenotype, the term "paraganglioma" is used [1].

About 10-20% of these rare endocrine tumors manifest in childhood, often being associated with genetic mutations [2], the incidence being 0.2-0.5 cases per 1 million children. This neoplastic entity, producing catecholamines and their metabolites, represents 80-85% of catecholamine-secreting tumors, about 80-90% of children being affected by hypertension at the time of diagnosis [3]. Most of these tumors are considered clinically benign, but about 10-15% of cases of pheochromocytomas and 20-50% of paragangliomas are potentially malignant forms [4]. However, both the "benign" and "malignant" forms of pheochromocytoma / paraganglioma are now appreciated to be potentially malignant forms, and a risk stratification approach is accepted to identify cases predisposed to metastatic spread in the future [5]. Pheochromocytoma may be associated with some cancer syndromes, namely, multiple endocrine neoplasia type 2 (MEN2), von Hippel-Lindau disease, type 1 neurofibromatosis, etc. [6].

This study aims to elucidate the case of a 9-year-old patient with hypertension and tachycardia, diagnosed with pheochromocytoma located retroperitoneally in the anterior region of the lower renal pole with compression of the right renal hilum and upper ureter, the right adrenal gland not being imagistically detected in the anatomical place.

Case presentation. The 9 years old girl was hospitalized in our institution for a retroperitoneal tumor formation, presenting with general weakness, pronounced headache, periodic abdominal pain, periodic nausea, hypertension. According to her parents, she found out that the disease started 4 years ago with a headache, later the rest of the mentioned symptoms appeared.

At the time of hospitalization, the general condition of the patient was stable, the blood pressure in both arms being 180/130 mmHg, and the pulse rate of 125 beats per minute.

After initiating the treatment with captopril and nifedipine, blood pressure dropped to 154/110 mmHg for a period of time, but after – returning to initial values. The results of routine laboratory tests, Electrocardiogram (ECG) and chest X-ray did not show any pathological deviations.

Abdominal ultrasound showed a retroperitoneal tumor on the right. Abdominal computed tomography confirmed the presence of a retroperitoneal tumor on the right located between the antero-medial surface of the lower half of the right kidney and the duodenum, measuring 5.6 x 5.7 x 6.1 cm, which unevenly captures the contrast substance (figure 1).

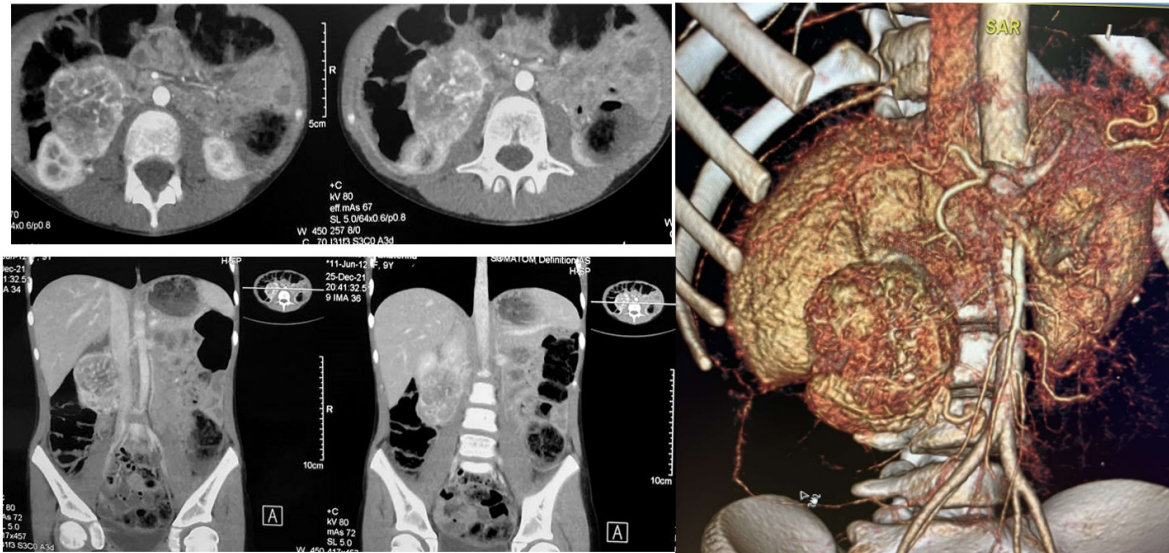


Figure 1. Patient, 9 years old. CT with intravenous contrast with iogexol performed preoperatively. Explanations in the text.

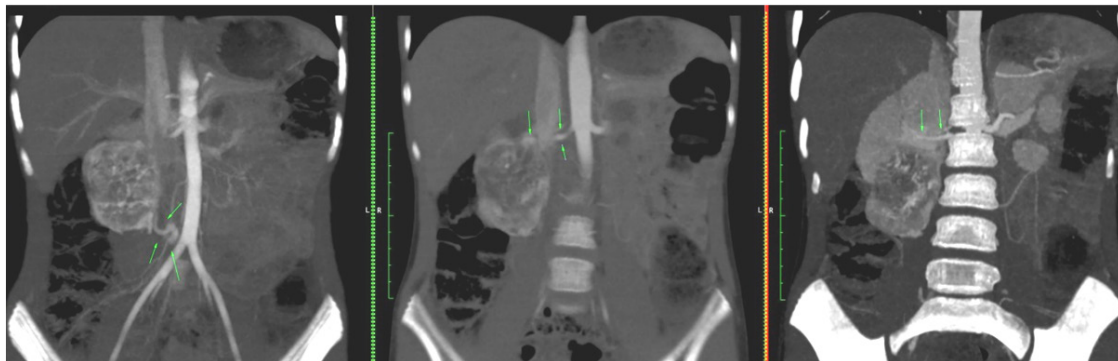


Figure 2. Patient, 9 years old. Contrast preoperative MRI: Heterotopic pheocarcinoma? Renal paraganglioma?

Contrasting Magnetic Resonance Imaging (MRI) of the abdomen revealed a heterogeneous volume formation, located anterior to the lower pole of the right kidney with clear capsular contour, with an intense inhomogeneous hypercontrastation predominantly peripheral, with central necrotic component, with compressive effect in the renal hilum, with no signs of renal structures and renal hilum invasion (figure 2).

The upper part of the formation is suspected to have a connection with a branch of the right renal artery, in the lower part – sinuous venous drainage with mesenteric vein. The adrenal gland on the right is not visible, the left – of normal size and structure. No signs of abdominal lymphadenopathy were found. Conclusion: ectopic pheochromocytoma? Renal paraganglioma?

Evaluation of free plasma catecholamine metabolites found increased levels of normetanephrine – 5217.9 pg/mL (norm: <196), methanephrine levels being within normal limits – 19.4 pg/mL (norm: <65). Testing of fractional urinary metanephrines revealed significantly increased values of normetanephrine – 5989.66 µg/24h (reference range for children aged 9-12 years: 55-422 µg/24h) and 3-methoxytyramine – 583.43 µg/24h (reference range: 192-228 µg/24h), while metanephrine values were within subnormal limits – <26.13 µg/24h (reference range: 43-188 µg/24h). At the same time, elevated serum aldosterone (41.6

ng/dL) and direct plasma renin (226.8 µUI/mL) were found, while the aldosterone / renin index was 0.18 (norm: <3.7).

After preoperative preparation using doxazosin, transabdominal surgery was performed. Intraoperatively, a tumor formation of about 5-6 cm in diameter was found, well vascularized, with a macronodular surface, of hard-elastic consistency, with anterior location from lower surface of the kidney, which was compressing the renal hilum without invading the organ. After mobilization with ligation and sectioning of blood vessels, an intimate adhesion of the ureter to the tumor was observed, being of a smaller size compared to the ureteral segment localized above the tumor. The tumor was removed radically without damaging the capsule (figure 3). No other formations were found. The operation ended with the restoration of the anatomical plane.

We note that, during the operation, hypertension crises and hypotensive reactions caused by the secretion of catecholamines were present, but which were controllable.

Histological examination established the diagnosis of pleiomorphocellular pheochromocytoma with alveolar zonal pattern (Zellballen), with vascular and necrotic thrombohemorrhagic foci (figure 4).

The results of the immunohistochemical test revealed a diffuse positive reaction of the cellular component to the marker Chromogranin-A and negative to Melan-A with a positive reaction in the sustentocyte cells at the periphery

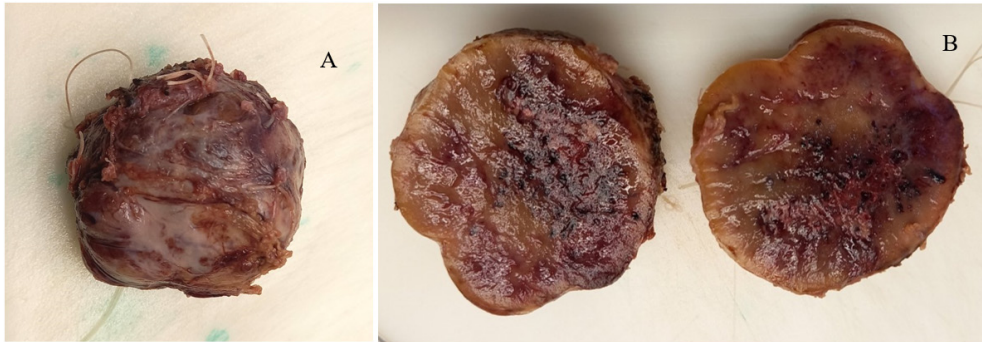


Figure 3. A – Macroscopic appearance of the removed tumor; B – the macroscopic sectioned appearance of the tumor, which has a yellowish-brown hue, at the subcapsular periphery a weakly differentiated yellowish area is determined; zonal, towards the center, there is an accentuation of the vascular network, which contains thrombi; foci of necrosis and hemorrhage.

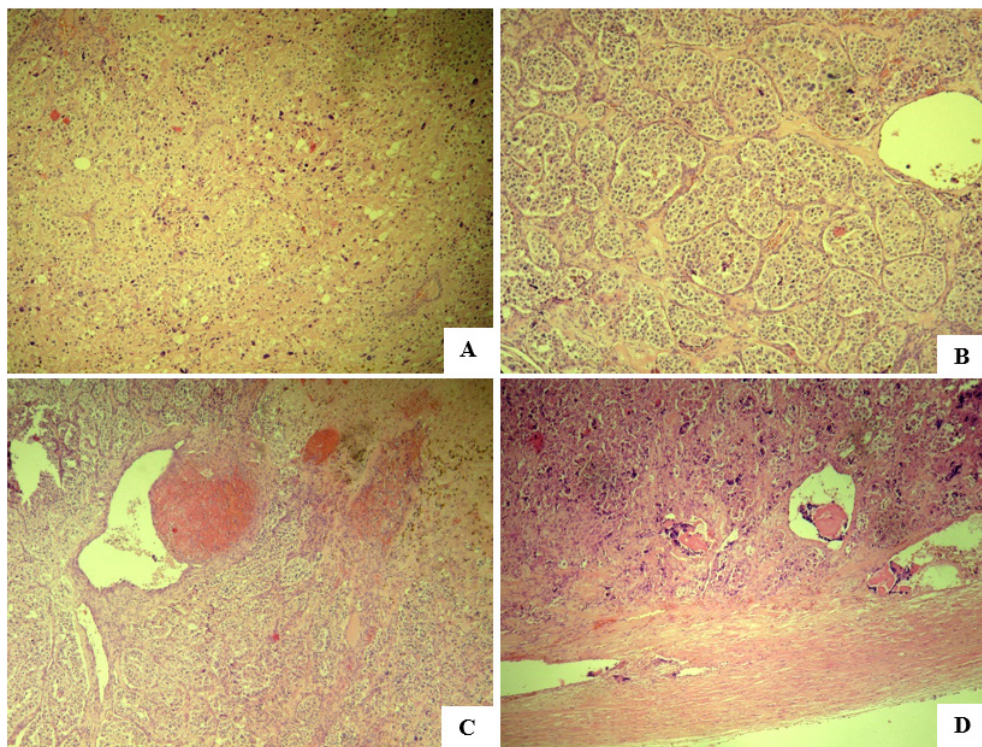


Figure 4. Microscopic aspect of ectopic adrenal neoplasm: A – Proliferation of chromophinic polygonal cells with nuclear polymorphism (irregular round nuclei, in various relation to bizarre pleomorphic nuclei with a more or less eosinophilic microgranular cytoplasm; B – Areas with uniform and non-uniform alveolar architecture characteristic to the Zellballen growth pattern; C – Parietal thrombosis in organization and revascularization (a) adjacent to an area of sclerosis with hemosiderosis and hemosiderophagy (b); D – Ectatic vessels in the peripheral area with protein-cell agglutinates with hyperchromic nuclei, some pleomorphic cells in the vessels from the capsule area.

of the tumor nests which confirms histological features of pheochromocytoma with no definite invasion of the capsule or lymphovascular area (LV0). PASS score – adrenal gland pheochromocytoma; Scaled Score = 4.

The postoperative period evolved with episodes of transient hypotension, the blood pressure returning to normal values 3-4 days after surgery. The patient was discharged on the 10th day postoperatively with a blood pressure of 110/60 mmHg and a pulse rate of 103 beats per minute.

The patients agreed to the publication of the clinical case.

Discussions

The adrenal glands have a double embryological origin, the cortex coming from the mesoderm while the medullary layer – from the ectoderm, histopathological differing in cell

structure, organization and function [7]. Embryologically, the adrenal cortex is derived from the coelomic mesoderm of the urogenital crest during the 4th and 5th week of fetal development. Chromaffin adrenal medulla is a component of the sympathetic nervous system. At the 7th-8th week of embryogenesis, the ectodermal cells of the neural crest separate from the celiac plexus and advance into the primordial cortex, thus developing the medullary layer of the adrenal gland. The aberrant or accessory adrenal glands are formed at the 7th and 8th week, with multiple or secondary primordia separated from the main gland. The adrenal cortex is completely differentiated in the three areas up to the age of 3 years [8].

Variations of the adrenal glands can be examined under four main criteria: absence, fusion ("Horseshoe" or

"Butterfly"), and incorrect position of the adrenal glands and ectopic adrenal glands [9, 10, 11]. Ectopic adrenal tissue, first described by Morgagni (1740), is a rare entity associated with embryological developmental defects, with an incidence ranging from 1% - 9.3%, although it can occur in 50% of newborns regressing later in early childhood. Most ectopic adrenal tissue is found in the vicinity of the adrenal glands around the celiac axis. However, because the adrenal cortex and gonads originate from the urogenital crest, in the early periods of embryogenesis the adrenal cortical tissue may migrate with the gonadal descent. Usually, ectopic adrenal tissue is asymptomatic, being found incidentally during surgery in various regions of the body, including: retroperitoneal space, renal parenchyma, celiac plexus, intrathoracic, hepatic capsule, spermatic cord, testis and surrounding tissues, etc. Ectopic adrenal tissue requires a differential diagnosis of volume formations closely related to the urogenital system or on the path of gonadal descent [8, 12, 13].

Adrenal heterotopia is rare when accessory adrenal tissue is incorporated into adjacent organs due to incomplete separation of primitive adrenal cortical cells from the celomic mesothelium. Adrenal heterotopia can be complete or partial, depending on when both or only one part of the adrenal gland does not remain in the normal anatomical position [8]. In the literature are described cases of malposition of the adrenal gland with various variations of both arterial and venous vascularization [10].

Some reports have shown cases of functional adrenocortical adenoma or adrenocortical carcinoma originating from ectopic adrenal tissue, but cases of pheochromocytoma from ectopic adrenal tissue are casuistic [14]. Cases of retroperitoneal pheochromocytoma are also reported randomly [15].

The first case of pheochromocytoma was described by Felix Frankel in 1886 [16, 17]. According to some authors, the German pathologist Ludwig Pick (1912) proposed the term "pheochromocytoma", which comes from the Greek words "phaios" (dark), "chroma" (color) and "cytoma" (tumor) [18], others believe that this term was invented by Poll H. (1905) [19]. Max Schttelius (1849-1919) first described the histopathological features of the pheochromocytoma [20]. In 1926, Charles Mayo and Cesar Roux first reported successful surgical removal of pheochromocytoma [21].

Symptoms of pheochromocytoma are caused by increased levels of catecholamines (dopamine, norepinephrine, epinephrine, etc.) in the circulation, causing high blood pressure, tachycardia, changes in cardiac conduction, headache, sweating, face hyperemia, nausea, vomiting, dizziness. In some cases, hypertensive retinopathy or papillary edema may be found [22].

Although the basic investigation in the primary detection of adrenal gland tumors is imaging (computed tomography and MRI), the gold standard in the diagnosis of pheochromocytoma and paraganglioma is the demonstration of excess catecholamine production [18, 23]. Evaluation of methanephrines in plasma or urine are primordial because they have a higher diagnostic accuracy

compared to catecholamine testing [24]. Depending on the biochemical phenotype, these tumors can be divided into 3 groups: noradrenergic tumors, which secrete mainly noradrenaline, adrenergic tumors which secrete mainly adrenaline, group 3 being composed of tumors in which predominantly dopamine is secreted [25]. The biochemical phenotype can be considered an indicator of tumor location. As an example, the secretion of adrenaline and metanephrine is usually characteristic for adrenal tumors, while extra-adrenal tumors secrete predominantly or exclusively noradrenaline and normetanephrine. Tumor production of 3-methoxytyramine is also associated with the extra-adrenal localization of the primary tumor [26, 27]. Some studies have found that the secretory phenotype of adrenal pheochromocytoma does not significantly influence the rate of hemodynamic complications during surgery, but may influence the postoperative outcome, noradrenergic tumors having worse outcomes than adrenergic ones, with higher rates of recurrence or malignant behavior [28].

Positron Emission Tomography (PET) scanning technology uses several radiolabeled ligands, involved in the synthesis and metabolism of catecholamines and can be used to locate this type of tumor. ¹²³I-methaiodobenzylguanidine scintigraphy, this substance being an analog to norepinephrine with major affinity for the transport of norepinephrine, is useful to locate these tumors [18, 29]. Simultaneous diagnosis of pheochromocytoma in both adrenal glands is called synchronous bilateral pheochromocytoma, while subsequent occurrence of pheochromocytoma in the contralateral adrenal gland after excision of unilateral pheochromocytoma is called metachronous bilateral pheochromocytoma [30].

Although the clinical manifestations of this tumor are quite clear, the correct diagnosis can often be confounded with adrenal neuroblastomas, about 20% of which have hypertension due to catecholamine release and compression of renal vessels. Another challenge is that some cases are normotensive, some authors reporting an incidence of about 12% of patients with pheochromocytoma. The non-secreting pheochromocytomas found in 4-13% of patients should be also taken into account. Therefore, adrenal tumors in children should be properly evaluated by a multidisciplinary team, and the exclusion of neuroblastoma is fundamental [31].

Composite pheochromocytoma is a very rare tumor of the adrenal medulla, which consists of neuroendocrine and neuronal components. Histologically, the endocrine portion is that of a pheochromocytoma, while the neuronal elements may represent neuroblastoma, ganglioneuroma, ganglioneuroblastoma, neuroendocrine carcinoma, or schwannoma. Although both pheochromocytomas and neurogenic tumors are derived from the neural crest, they are distinct entities. Symptoms can result from hypersecretion of hormones by any of the components [32].

Preoperative management of pheochromocytoma is aimed at controlling hypertension, heart rate and arrhythmia, evaluation and optimization of the myocardial function, restoration of circulating blood volume, electrolyte disorders removal and glucose levels normalization [33]. Preoperative

preparation can take about 2-4 weeks and includes the use of α -adrenoceptor antagonists, which are the first-choice preparations (phenoxybanzamine, doxazosin). Calcium channel blockers may be used in some cases to improve blood pressure control. The use of β -adrenoceptor antagonists is determined by the presence and severity of tachycardia, these preparations being indicated after an adequate blockade of α -adrenoceptors. The inhibitor of catecholamine synthesis, methyrosine, is used in combination with α -adrenoceptor antagonists in patients with severe symptoms, such as those with biochemically active tumors or extensive metastatic tumors. It is recommended the treatment of these tumors to include, also, a high-sodium diet and an adequate fluid intake to restore the preoperative blood volume and prevent perioperative hypotension [34, 35, 36].

Surgical resection is the treatment of choice for patients with pheochromocytoma. Laparoscopic removal of pheochromocytoma is the preferred treatment, whereas in cases of a large tumor or difficult-to-approach paragangliomas, open laparotomy is recommended, depending on the

location, and the surgeon's preference a transperitoneal or retroperitoneal approach is performed [37, 38].

Conclusion

The described case is of interest due to an atypical position with a varied vascularization of the pheochromocytoma, located retroperitoneally on the right, described casuistically in the literature, which created some diagnostic confusions. The use of the transperitoneal approach in this case allowed an excellent exposure and radical removal of the tumor without injury to the kidney and ureter attached to the tumor. Despite the ligation of the main vein of the tumor, during the surgical intervention, hypertensive ascents were found due to an abundant vascularization of the neoplasm without compromising the systemic hemodynamics. Preoperative use of selective postsynaptic α 1-adrenergic receptor blockers such as doxazosin in combination with calcium channel blockers (amlodipine) has provided a relatively adequate control of hypertension in children with heterotopic pheochromocytoma.

Bibliography

1. Lenders JW, Pacak K, Walther MM, et al. Biochemical diagnosis of pheochromocytoma: which test is best?. *JAMA*. 2002;287(11):1427-1434. doi:10.1001/jama.287.11.1427
2. Carrasquillo JA, Chen CC, Jha A, et al. Imaging of Pheochromocytoma and Paraganglioma. *J Nucl Med*. 2021;62(8):1033-1042. doi:10.2967/jnumed.120.259689
3. Whitelaw BC, Prague JK, Mustafa OG, et al. Phaeochromocytoma [corrected] crisis [published correction appears in *Clin Endocrinol (Oxf)*. 2013 Mar;80(3):468]. *Clin Endocrinol (Oxf)*. 2014;80(1):13-22. doi:10.1111/cen.12324
4. Gunawan VL, Suarta K, Nilawati GAP, et al. Bilateral adrenal pheochromocytomas in a 14 year-old boy. *J Pediatr Surg Case Rep*. 2019;51(101318):101318. doi:10.1016/j.epsc.2019.101318.
5. Juhlin CC. Challenges in Paragangliomas and Pheochromocytomas: from Histology to Molecular Immunohistochemistry. *Endocr Pathol*. 2021;32(2):228-244. doi:10.1007/s12022-021-09675-0
6. Dias Pereira B, Nunes da Silva T, Bernardo AT, et al. A Clinical Roadmap to Investigate the Genetic Basis of Pediatric Pheochromocytoma: Which Genes Should Physicians Think About?. *Int J Endocrinol*. 2018;2018:8470642. Published 2018 Mar 20. doi:10.1155/2018/8470642
7. Ross IL, Louw GJ. Embryological and molecular development of the adrenal glands. *Clin Anat*. 2015;28(2):235-242. doi:10.1002/ca.22422
8. Barwick TD, Malhotra A, Webb JA, Savage MO, Reznick RH. Embryology of the adrenal glands and its relevance to diagnostic imaging. *Clin Radiol*. 2005;60(9):953-959. doi:10.1016/j.crad.2005.04.006
9. Vachharajani A, Bethin K, Mouillet JF, Sadovsky Y, Saunders S. The rare occurrence of absent adrenals in a term infant: a case report and review of the literature. *Am J Perinatol*. 2006;23(2):111-114. doi:10.1055/s-2006-931911
10. Oztürk NC, Uzansel D, Kara A, Oztürk H. Variation in the position, relation and vasculature of left suprarenal gland: a case report. *Surg Radiol Anat*. 2010;32(10):985-988. doi:10.1007/s00276-010-0636-2
11. Ditkofsky N, Bradley N, Jeon P. Horseshoe adrenal gland: a rare congenital anomaly. *Surg Radiol Anat*. 2013;35(8):749-754. doi:10.1007/s00276-013-1105-5
12. Zihni İ, Karaköse O, Yılmaz S, Özçelik KÇ, Pülat H, Demir D. Ectopic Adrenal Gland Tissue In The Inguinal Hernia Sac Occuring In An Adult. *Turk J Surg*. 2020;36(3):321-323. Published 2020 Sep 28. doi:10.47717/turksurg.2020.3255
13. Sensu S, Keser SH, Gurbuz Y, Barisik NO, Gul AE. Clinicopathological Evaluation of 15 Ectopic Adrenal Tissues. *Arch Iran Med*. 2021;24(4):301-305. Published 2021 Apr 1. doi:10.34172/aim.2021.42
14. Ohsugi H, Takizawa N, Kinoshita H, Matsuda T. Pheochromocytoma arising from an ectopic adrenal tissue in multiple endocrine neoplasia type 2A. *Endocrinol Diabetes Metab Case Rep*. Published online October 12, 2019. doi:10.1530/EDM-19-0073
15. Rey Chaves CE, Ayala D, García G, Conde Monroy D, Sabogal Olarte JC. Retroperitoneal pheochromocytoma: Unusual presentation and atypical location. *Int J Surg Case Rep*. 2021;85:106248. doi:10.1016/j.ijscr.2021.106248
16. Donckier JE, Michel L. Phaeochromocytoma: state-of-the-art. *Acta Chir Belg*. 2010;110(2):140-148. doi:10.1080/00015458.2010.11680587
17. Serras I, Baptista RB, Francisco T, Casimiro A, Lito D, et al. Coexistence of pheochromocytoma and renal artery stenosis in a pediatric patient with hypertension. *Port. J. Nephrol. Hypert*. 2018;32(1):78-82.
18. Tevosian SG, Ghayee HK. Pheochromocytomas and Paragangliomas. *Endocrinol Metab Clin North Am*. 2019;48(4):727-750. doi:10.1016/j.ecl.2019.08.006
19. Thompson LD. Pheochromocytoma of the Adrenal gland Scaled Score (PASS) to separate benign from malignant neoplasms: a clinicopathologic and immunophenotypic study of 100 cases. *Am J Surg Pathol*. 2002;26(5):551-566. doi:10.1097/00000478-200205000-00002

20. Neumann HPH, Young WF Jr, Eng C. Pheochromocytoma and Paraganglioma. *N Engl J Med.* 2019;381(6):552-565. doi:10.1056/NEJMra1806651
21. Welbourn RB. Early surgical history of phaeochromocytoma. *Br J Surg.* 1987;74(7):594-596. doi:10.1002/bjs.1800740717
22. Zerhouni H, Kaddouri N, Abdelhak M, Benhmmamouch N, Barahioui M. Le phéochromocytome de l'enfant. A propos de deux cas [Pheochromocytoma in children. Two case reports]. *Ann Urol (Paris).* 2002;36(2):87-94. doi:10.1016/s0003-4401(01)00079-1 (French)
23. Sarathi V, Pandit R, Patil VK, Lia AR, Bandgar TR, Shah NS. Performance of plasma fractionated free metanephrines by enzyme immunoassay in the diagnosis of pheochromocytoma and paraganglioma in children. *Endocr Pract.* 2012;18(5):694-699. doi:10.4158/EP12050.OR
24. Lenders JWM, Eisenhofer G. Update on Modern Management of Pheochromocytoma and Paraganglioma. *Endocrinol Metab (Seoul).* 2017;32(2):152-161. doi:10.3803/EnM.2017.32.2.152
25. Eisenhofer G, Lenders JW, Goldstein DS, et al. Pheochromocytoma catecholamine phenotypes and prediction of tumor size and location by use of plasma free metanephrines. *Clin Chem.* 2005;51(4):735-744. doi:10.1373/clinchem.2004.045484
26. Funahashi H, Imai T, Tanaka Y, et al. Discrepancy between PNMT presence and relative lack of adrenaline production in extra-adrenal pheochromocytoma. *J Surg Oncol.* 1994;57(3):196-200. doi:10.1002/jso.2930570312
27. van Berkel A, Lenders JW, Timmers HJ. Diagnosis of endocrine disease: Biochemical diagnosis of phaeochromocytoma and paraganglioma. *Eur J Endocrinol.* 2014;170(3):R109-R119. Published 2014 Feb 4. doi:10.1530/EJE-13-0882
28. Furnica RM, Dusoruth MM, Persu A, Gruson D, Mourad M, Maiter D. Influence of secretory phenotype and preoperative preparation on surgical outcome in pheochromocytoma. *Endocr Connect.* 2021;10(1):92-101. doi:10.1530/EC-20-0537
29. Park H, Kim MS, Lee J, et al. Clinical Presentation and Treatment Outcomes of Children and Adolescents With Pheochromocytoma and Paraganglioma in a Single Center in Korea. *Front Endocrinol (Lausanne).* 2021;11:610746. Published 2021 Jan 29. doi:10.3389/fendo.2020.610746
30. Sarathi V. Characteristics of Pediatric Pheochromocytoma/paraganglioma. *Indian J Endocrinol Metab.* 2017;21(3):470-474. doi:10.4103/ijem.IJEM_558_16
31. Younes A, Elgendy A, Zekri W, et al. Operative management and outcomes in children with pheochromocytoma. *Asian J Surg.* 2022;45(1):419-424. doi:10.1016/j.asjsur.2021.07.029
32. Steen O, Fernando J, Ramsay J, Prebtani AP. An unusual case of a composite pheochromocytoma with neuroblastoma. *J Endocrinol Metab.* 2014;4(1):39-46.
33. Strauss L. A practical approach to children with phaeochromocytomas and paragangliomas. *South. Afr. J. Anaesth. Analg.* 2018;24(3):S43-S48.
34. Romero M, Kapur G, Baracco R, Valentini RP, Mattoo TK, Jain A. Treatment of Hypertension in Children With Catecholamine-Secreting Tumors: A Systematic Approach. *J Clin Hypertens (Greenwich).* 2015;17(9):720-725. doi:10.1111/jch.12571
35. Fang F, Ding L, He Q, Liu M. Preoperative Management of Pheochromocytoma and Paraganglioma. *Front Endocrinol (Lausanne).* 2020;11:586795. Published 2020 Sep 29. doi:10.3389/fendo.2020.586795
36. Seamon ML, Yamaguchi I. Hypertension in Pheochromocytoma and Paraganglioma: Evaluation and Management in Pediatric Patients. *Curr Hypertens Rep.* 2021;23(5):32. Published 2021 May 27. doi:10.1007/s11906-021-01150-9
37. Jain A, Baracco R, Kapur G. Pheochromocytoma and paraganglioma—an update on diagnosis, evaluation, and management. *Pediatr Nephrol.* 2020;35(4):581-594. doi:10.1007/s00467-018-4181-2
38. Ban EJ, Yap Z, Kandil E, et al. Hemodynamic stability during adrenalectomy for pheochromocytoma: A case control study of posterior retroperitoneal vs lateral transperitoneal approaches. *Medicine (Baltimore).* 2020;99(7):e19104. doi:10.1097/MD.00000000000019104

Received – 02.08.2023, accepted for publication – 14.04.2024

Corresponding author: Igor Ambros, e-mail: igorambros2000@yahoo.com

Conflict of interest Statement: The authors reports no conflicts of interest in this work.

Funding Statement: The authors reports no financial support.

Citation: Babuci S, Petrovici V, Negru I, Ambros I, Berbeca A, Pasivcovchi T, Malțev M. A case of pheochromocytoma arising from heterotopic adrenal gland in children. *Arta Medica.* 2024;90(1):49-54.