

## CLINICAL CASES



DOI: 10.5281/zenodo.8213294

UDC: 617.54-001.4+616.25-003.24+616.711.5-001.5

# BLUNT CHEST INJURY WITH CHYLOTHORAX AND THORACIC VERTEBRAL FRACTURE - MULTIDISCIPLINARY MANAGEMENT

Aurelia Burduniuc<sup>1,2</sup>, Petr Habal<sup>1,2</sup><sup>1</sup> University Hospital Hradec Králové, Department of Cardiosurgery, Hradec Kralove, Czech Republic;<sup>2</sup> Charles University, Faculty of Medicine in Hradec Králové, Hradec Kralove, Czech Republic

## Summary

**Introduction.** Chylothorax is the result of traumatic as well as nontraumatic events. The conservative approach is usually applied in the management of chylothorax. Surgical treatment is not commonly used and is considered only in specific patients.

**Case presentation.** We describe a complicated algorithm that was used in treating a 70-year-old woman with Bechterew's disease. Admitted for healthcare after a fall, she suffered from a blunt chest injury with subsequent right-sided serial rib fracture with hemothorax and thoracic vertebral body fracture. The hyperextension of the ossified thoracic spine associated with Bechterew's disease caused the injury of the thoracic lymphatic duct. Simultaneous thoracic spine stabilization and surgical revision of the thoracic lymphatic duct from an anterior approach were indicated. Despite the urgency of thoracic spine stabilization, the procedure was postponed due to acute coronary syndrome, which was treated with drug-eluting stent insertion with a subsequent need for dual antiplatelet therapy. Thus, the procedure was performed 16 days after stent insertion.

**Conclusion.** The diagnosis of chylothorax must be considered in case of thoracic injury with continuing waste to the chest tube and detection of well-expanded pulmonary parenchyma. Biochemical investigation of the effusion is the cornerstone in establishing the diagnosis of chylothorax.

**Keywords:** chest trauma, chylothorax, thoracic vertebrae fracture, ductus thoracicus

## Introduction

Chylothorax is an accumulation of chyle in the pleural cavity. The chyle is an opalescent liquid with a high content of triglycerides and chylomicrons, proteins, electrolytes, immunoglobulins and fat-soluble vitamins, transported from the gastro-intestinal system into the bloodstream by the thoracic duct. In adults, it makes up about 1-3% of the total body weight [1].

The cranial direction of the lymph flow is ensured by respiratory mechanisms, negative pressure in the pleural cavity and the valve system [2].

Chylothorax is caused by the discontinuity of the lymphatic duct wall or one of the large branches of its collaterals. It is generally categorized as traumatic, less common or nontraumatic. The mechanism of the injury can be penetrating, blunt, and barotrauma [3].

It can be caused by chest compression, as well as by

a change in intrathoracic pressure during coughing or persistent vomiting [4]. The actual lesion of the lymph duct wall can be at any point along its course in the chest cavity. The prevalence of chylothorax is around 0.5-2% [5]. The traumatic cause accounts for about 49% of cases [4].

The symptoms of chylothorax are initially very similar to those of any fluidothorax. Diagnosis is difficult in cases complicated by post-traumatic hemothorax. The cause cannot be diagnosed with conventional X-ray imaging methods. Computer Tomography (CT) native scan of the thorax and the measurement of the density of effusions are beneficial. The average density of normal effusion is up to 10 HU (Hounsfield units). If the density of the effusion is around 60 HU, it is a hemothorax, if it is in minus values, it is with great certainty a chylothorax. The density is increased by the protein present in the blood coagulum and decreased by lipids [6]. A biochemical examination of the pleural effusion

**Table 1**

Physiological composition of lymphatic fluid

<b>Lipids</b>	4 - 50 g/l	<b>Lymphocytes</b>	0,4 – 6,8/ml
<b>Cholesterol</b>	0,6 - 2,2 g/l	<b>Erythrocytes</b>	0,05 – 0,6/ml
<b>Albumin</b>	22 - 60 g/l	<b>Fibrinogen</b>	25 % of blood plasma
<b>Globulin</b>	12 - 36 g/l	<b>Prothrombin</b>	25 % of blood plasma
<b>Fibrinogen</b>	16 - 240 g/l	<b>Electrolytes</b>	Similar to blood plasma

Adjusted according to: Miller jr. JI. Anatomy of the thoracic duct and chylothorax. In Shields, TW, Lo Cicero J, Ponn RB. (Eds), *General Thoracic, Vol 1, 5th ed. Philadelphia: Lippincott Williams and Wilkins, 2000; 1591.*

is necessary to establish the diagnosis with certainty. The biochemical composition of lymph is presented in Table 1.

**Case study**

A 70-year-old woman with Bechterev's disease and other internal diseases was admitted to the intensive care unit of the Cardiac Surgery Clinic of the Faculty of Medicine and the University Hospital in Hradec Králové.

The patient was suffering from a multitude of diseases, but the two that have complicated the course of hospitalization were chronic obstructive pulmonary disease (COPD) and ischemic heart disease (IHD).

She was brought to the hospital because of a fall on the stairs that led to a blunt injury to the right half of her chest. After the initial X-ray and CT examination at the Department of Emergency Medicine, a large right-sided effusion with a serial fracture of 5th-8th ribs in the right front axillary line was detected. The most serious injury to the thoracic spine was a fracture of the Th12 vertebral body with a 20 mm *ad latus* defect (Figure 1). The patient was admitted to the intermediate care unit of the Cardiac Surgery Clinic of the University Hospital in Hradec Králové. The effusion was drained in the 6th intercostal space in the middle axillary line on the right, 850 ml of blood was evacuated once. The blood loss did not continue. On the third day after the injury a chylous fluid appeared in the chest drain. The daily fluid production was around 1500 - 1800 ml. A biochemical analysis of the drained fluid confirmed the suspected diagnosis of traumatic chylothorax (Table 2). Due to the very unstable nature of the fracture, the neurosurgeon indicated an early stabilisation operation of the thoracic spine from the anterior transthoracic approach (Figure 2). Up until this point, the patient did not have neurological symptomatology. During the preoperative period, the patient showed signs of unstable angina pectoris, objectified by a rise in troponin and an alteration of the cardiac circulation. Circulatory instability required catecholamine support and urgent coronary angiography was performed.

**Table 2**  
*Serum and pleural fluid total protein and lipid values*

	Serum	Pleural fluid
Total protein (mmol/l)	54,6	29,7
Triglycerides (mmol/l)	1,72	19,38
Cholesterol (mmol/l)	3,54	2,13

Critical stenosis of the dominant right coronary artery was detected, requiring angioplasty with the introduction of a coated stent. The acute coronary event complicated the actual surgical management of the injured thoracic spine and chylothorax, because it was necessary to administer dual antiplatelet treatment for at least 14 days on the recommendation of the interventional cardiologist. After discontinuation of dual antiplatelet therapy, the patient was switched to low-molecular-weight heparin, so that a joint operation by a thoracic surgeon and a neurosurgeon was performed on the 18th day after the injury. First,

from the right lower posterolateral thoracotomy in the 7th intercostal space, the pleural cavity was opened, where there were numerous pleuropulmonary adhesions formed as a consequence of initial hemothorax and some residual hemothorax.

By dissection in the area of the internal costophrenic angle, just above the diaphragm, on the front surface of the body of the thoracic vertebra, the course of the thoracic lymph duct was found and its ligation was performed. Next, a partial corpectomy of the upper 1/3 of the Th12 vertebral body was performed, and the X Pand R (Globus Medical, AUDUBON, Pennsylvania) implant was inserted into the created bed, which, after expansion, was filled with bone graft. The spine was fixed from the lateral side in the Th11 – L1 range with a Thoracolumbar spine locking plate (TSLP). A chest drain was inserted, which was connected to chest suction.

The postoperative course was complicated by circulatory instability due to cardiac decompensation with a reduced cardiac ejection fraction of 45% after a non-transmural myocardial infarction. Respiratory insufficiency due to COPD required ventilation and was accelerated by nosocomial pneumonia. After 12 days of artificial lung ventilation the patient was disconnected.

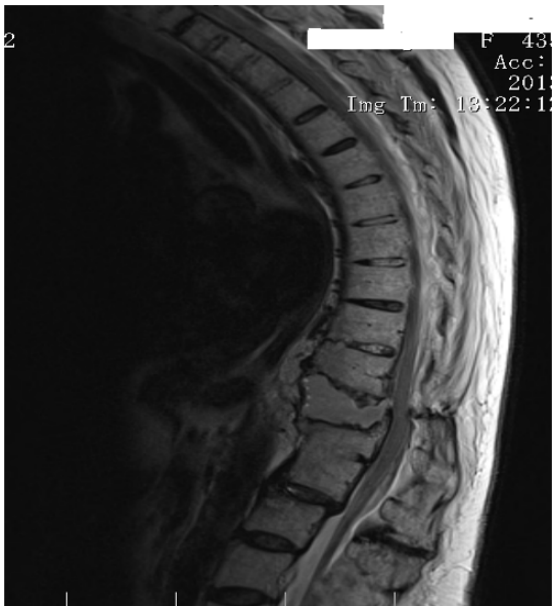The chest drain was removed on the 6th postoperative day, when the waste was below 200 ml per 24 hours of serosanguinolent fluid. Control x-ray of the lungs did not show a fluidothorax. But on control CT examination, residual fluidothorax was detected, along with inflammatory infiltration in the right lower lung field and a good position of the fixed comminuted fracture of the Th12 thoracic vertebra (Figure 3). Total chest drain waste in the postoperative period was 2850 ml. However, according to the biochemical examination, the fluid did not have a chylous character (Table 3). The character of the drained fluid was at the beginning hemorrhagic and later – serosanguinolent. The patient was transferred to a rehabilitation facility for further rehabilitation. Prior to the transfer, we asked the patient for her informed consent. The patients agreed to the publication of the clinical case.

**Table 3**  
*Lipid and total protein values in the pleural fluid*

	Before surgery	After surgery
LD (µkat/l)	8,79	1,27
Cholesterol (mmol/l)	2,13	0,44
TAG (mmol/l)	19,38	0,16
Total protein (g/l)	29,7	26,3

**Discussion**

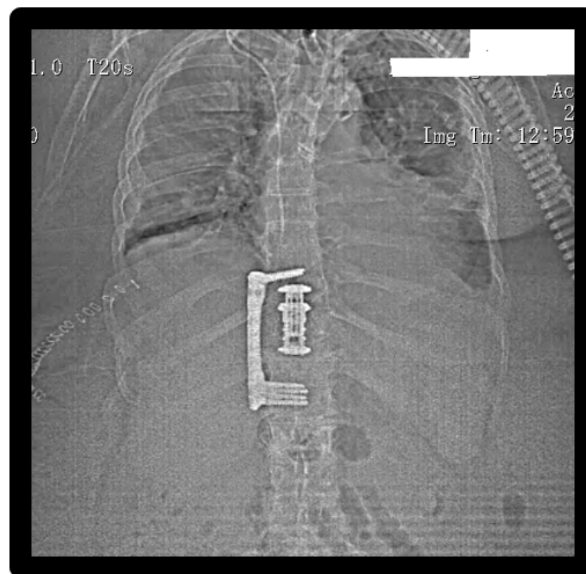
Blunt chest injuries by various mechanisms are common. In our experience, around 90% of all chest injuries. Only a certain small part of patients is indicated for surgical intervention, mostly for an unstable chest wall with signs of respiratory insufficiency [7]. Even in the case of high-energy blunt injuries, when there were serial block fractures of the ribs with the necessity of surgical stabilization of the



**Figure 1.** MRI image of the comminuted fracture of the Th12 vertebra



**Figure 2.** MRI 3D reconstruction of the comminuted fracture of the Th12 vertebra



**Figure 3.** X-ray image after the stabilization of the thoracic spine

chest wall, injury to the lymphatic duct is not observed [8]. Combined injuries of the chest and thoracic vertebrae are not common. If chest trauma is complicated by fracture of the vertebral bodies, chylothorax may occur in up to 20% of cases [9]. In Bechterev's disease, the primary inflammatory disease causes limited mobility, which causes a change in the position of the vertebral bodies. Then, even a small inducing external force will cause a fracture of the vertebral body with dislocation and injury to the thoracic lymphatic duct.

The most common mechanism is arcuate tension through the diaphragmatic crura and their attachments to the vertebral bodies. This happens with hyperextension of the thoracic spine [10]. Conservative therapy of fracture of vertebral bodies by external immobilization does not bring good results. The basis is surgical treatment of the fracture with reduction and stabilization.

Chylothorax does not always appear immediately after the injury, rare cases of occurrence even after several weeks

have been published [11].

Chylothorax of non-traumatic etiology can be encountered sporadically in thoracic surgery after lung resections of central lung tumors. In these cases, conservative treatment with restriction of lipid intake and total parenteral nutrition is usually successful. This is due to the fact that usually in these instances the branches of the main lymph duct are injured, not the main lymph duct itself. The incidence of chylothorax as a pulmonary surgery complication is reported to be around 1% [12]. Very rarely, iatrogenic chylothorax can be a complication of heart surgery. It is described in less than 0.1% of cases after dissection of the left mammary artery. This is a complication that prolongs the hospitalization of patients, conservative parenteral nutrition started in time will allow spontaneous healing of the defect [13].

Chylothorax is a much-feared complication of long-term usage of the Vacuum Assisted Closure system (V.A.C.) on the area of the anterior mediastinum, which was not confirmed

in a patient with sternal osteomyelitis after cardiac surgery. However, a broncho-pleuro-cutaneous fistula occurred, requiring an atypical lung resection [14]. Conservative treatment of non-traumatic chylothorax is often successful. In addition to total parenteral nutrition with restriction of oral intake, evacuation chest drainage with permanent pressure to -20 cm H<sub>2</sub>O is required for permanent evacuation. This is the only way to ensure long-term good adhesion conditions of the lung wing to the mediastinal section of the lymphatic duct. The administration of somatostatin, which reduces the formation of chyle in the gastrointestinal tract, is also recommended [15]. Opinions differ as to how long one can proceed conservatively. If chest drain wastes greater than 1500 ml of proven chyle per day and persist for more than 5 days, there is little hope for conservative healing of chylothorax of any aetiology [16].

### Conclusion

Traumatic chylothorax is not common, which is why there

are no larger reports of patients, usually only case reports. From individual literature reports, the opinion emerges that the duration of conservative treatment should not be extended too much. This affects the patient's metabolism, malnutrition, and can lead to the development of nosocomial lung infections in the case of a permanently compressed lung wing.

The postponement of surgical treatment in our case was motivated by the necessity to allow at least partial endothelialization of the introduced DES stent into the right coronary artery. The short duration of dual antiplatelet therapy was an empirical compromise agreed on by several cardiologists and the neurosurgeon that was well aware of the risks of neurological complications in case of surgery delay of the unstable vertebral body fracture. This rare case showed the necessity of connecting specialists of different surgical fields in causal treatment. The good final result only confirmed the already well-functioning cooperation between thoracic surgeons and neurosurgeons [17].

### Bibliography

1. Carola R, Halley JP, Noback Ch. Human anatomy and physiology. McGraw-Hill. New York. 1990.
2. Petrenko VM, Kruglov SV. Klapany grudnogo protoka cheloveka i beloï krysy [Thoracic duct valves in man and albino rat]. *Morfologija*. 2004;126(6):40-42. (Russian)
3. Smejkal K, Ivák I, Holecek T, Habal P, Lochman P. Ischemic affection of the spinal cord as a result of the blunt thoracic trauma--a case report. *Rozhl Chir*. 2008;87(7):344-346.
4. Doerr CH, Allen MS, Nichols FC 3rd, Ryu JH. Etiology of chylothorax in 203 patients. *Mayo Clin Proc*. 2005;80(7):867-870. doi:10.4065/80.7.867
5. Sachs PB, Zelch MG, Rice TW, Geisinger MA, Risius B, Lammert GK. Diagnosis and localization of laceration of the thoracic duct: usefulness of lymphangiography and CT. *AJR Am J Roentgenol*. 1991;157(4):703-705. doi:10.2214/ajr.157.4.1892021
6. Aquino SL, Webb WR, Gushiken BJ. Pleural exudates and transudates: diagnosis with contrast-enhanced CT. *Radiology*. 1994;192(3):803-808. doi:10.1148/radiology.192.3.8058951
7. Habal P, Simek J, Stětina M, Novotný J. Casná chirurgická stabilizace hrudníku [Early surgical stabilization of the thorax]. *Rozhl Chir*. 2002;81(4):167-169. (Czech)
8. Habal P, Simek J, Novotný J. Dvoudobá chirurgická stabilizace hrudní steny pro dechovou nedostatečnost -- kazuistika [The two-stage surgical stabilization of the chest wall trauma with respiratory insufficiency -- a case report]. *Acta Medica (Hradec Kralove) Suppl*. 2003;46(1-2):75-77. (Czech)
9. Ikonomidis JS, Boulanger BR, Breneman FD. Chylothorax after blunt chest trauma: a report of 2 cases. *Can J Surg*. 1997;40(2):135-138.
10. BIRT AB, CONNOLLY NK. Traumatic chylothorax: a report of a case and a survey of the literature. *Br J Surg*. 1952;39(158):564-568. doi:10.1002/bjs.18003915822
11. Milano S, Maroldi R, Vezzoli G, Bozzola G, Battaglia G, Mombelloni G. Chylothorax after blunt chest trauma: an unusual case with a long latent period. *Thorac Cardiovasc Surg*. 1994;42(3):187-190. doi:10.1055/s-2007-1016485
12. Le Pimpec-Barthes F, D'Attellis N, Dujon A, Legman P, Riquet M. Chylothorax complicating pulmonary resection. *Ann Thorac Surg*. 2002;73(6):1714-1719. doi:10.1016/s0003-4975(02)03570-1
13. Mand'ák J, Habal P, Stětina M, Harrer J. Chylothorax--a rare complication after cardiac surgery (a case report). *Acta Medica (Hradec Kralove)*. 2011;54(1):37-39.
14. Omran N, Habal P, Mandak J, Chek JL. Broncho-pleural fistula following vacuum-assisted closure therapy. *J Card Surg*. 2013;28(4):397-398. doi:10.1111/jocs.12126
15. Gómez-Caro Andrés A, Marrón Fernández C, Moradiellos Díez FJ, Díaz-Hellín Gude V, Pérez Antón JA, Martín de Nicolás JL. Tratamiento conservador con octreótido del quilotorax posquirúrgico [Octreotide for conservative management of postoperative chylothorax]. *Arch Bronconeumol*. 2004;40(10):473-475. doi:10.1016/s1579-2129(06)60357-1 (Spanish)
16. Selle JG, Snyder WH 3rd, Schreiber JT. Chylothorax: indications for surgery. *Ann Surg*. 1973;177(2):245-249. doi:10.1097/0000658-197302000-00022
17. Habal P, Kaltofen K, Kostyšyn R, Stětina M, Málek V. Fibrous dysplasia of ribs and spine: multidisciplinary solution -- a case report. *Cesk Slov Neurol N*. 2010;73/106(6):734-737.

Received – 25.04.2023, accepted for publication – 24.07.2023

**Corresponding author:** Aurelia Burduniuc, e-mail: burduniucaurelia@gmail.com

**Conflict of interest Statement:** The author reports no conflicts of interest in this work.

**Funding Statement:** Supported by MH CZ-DRO (UHHK, 00179906)

**Citation:** Burduniuc A, Habal P. Blunt chest injury with chylothorax and thoracic vertebral fracture - multidisciplinary management. *Arta Medica*. 2023;87(2):138-141.