

CLINICAL CASES



DOI: 10.5281/zenodo.7830907

UDC: 616.24-007.43-02:617.54-001.3

LUNG HERNIATION FOLLOWING BLUNT THORACIC TRAUMA: CASE REPORT

Serghei Guțu^{1,2}, Ion Burlacu^{1,2}, Igor Maxim^{1,2}¹ "Nicolae Testemitanu" State University of Medicine and Pharmacy, Chișinău, Republic of Moldova² Department of Thoracic Surgery, Institute of Emergency Medicine, Chișinău, Republic of Moldova

Summary

Introduction. Lung herniation following blunt force is a very rare occurrence of thoracic trauma with very few reported cases in medical literature. It can be defined as a protrusion of the pleural-covered parenchyma of the lung through an abnormal defect or chest wall weakness. It can also appear following thoracic surgery and can be classified based on location as parasternal, intercostal and supraclavicular.

Case Presentation. A 60-year-old male was admitted to our hospital by emergency services following blunt thoracic trauma to head, chest, abdomen and lower and upper extremities. Upon admission, chest Computed Tomography was performed that showed a small herniation of left lung through 4th intercostal space and close to left parasternal line. He underwent surgical intervention for closure of lung hernia by mini-access thoracoplasty. There were no signs of recurrence after one month and three months of follow-up.

Conclusions. Being a rare pathology, lung herniation is often overlooked in initial patient assessment, especially in a polytrauma patient where many clinical signs can often overlay one another. There is still no consensus regarding the surgical treatment of a pulmonary hernia. This can be done directly (primary) or delayed (secondary) and depends on the clinical condition of the patient.

Keywords: lung herniation, blunt trauma, chest wall, hernia

Introduction

Lung herniation is a condition that can be defined as a protrusion of pleural-covered lung parenchyma through an abnormal defect or weakness in the thoracic wall [1]. Causes of lung hernia are thoracotomy, chest trauma, and spontaneous occurrence. Its presence with other more common complications, like pneumothorax, haemothorax and subcutaneous emphysema may delay its diagnosis and can be determined by the use of computed tomography of the chest. Even though complications like tension pneumothorax, incarceration and strangulation of the lung parenchyma are uncommon, surgical treatment of the hernia should be considered in any case [2]. For symptomatic lung herniation, surgical repair is generally recommended, if no surgical contraindications exist. Thoracotomy is more widely used than the thoracoscopic approach. Pericostal fixation of adjacent ribs with sutures is the most common way to repair chest wall defects; however, several other methods had been reported [3]. We reported this rare case of a 60-year-old man who developed an intercostal herniation after blunt thoracic trauma. We repaired the chest wall defect with surrounding tissues.

Case presentation

A 60-year-old man, with history of chronic alcohol consumption, was physically assaulted, and presented to our emergency room 6 days after assault complaining of dyspnea, cough, pain in left hemithorax and gradual evo-

lution of subcutaneous emphysema that started 2 days prior admission. Physical examination revealed multiple bruises on head, thorax, abdomen, and both lower and upper extremities. Local tenderness of left hemithorax. A tender, 6cm x 5cm, mass was identified over left chest wall an abnormal movement of anterior left thoracic wall was observed with no signs of erythema or ecchymosis (Figure 1).

Blood examination showed signs of inflammation (white blood cell count of 13,400/ μ L, C-reactive protein concentration of 44.4 mg/L). Also, the patient presented elevated levels of D-dimer of 6220 ng/mL, Myoglobin of 377,49 ng/ml and Creatine kinase myocardial band (CK-MB) of 10,09 ng/mL more suggestive in the patient scenarios as a heart concussion that was monitored closely during his hospital stay. The patient underwent Computed Tomography of the Chest that showed the lung protruding through a chest wall defect, with bilateral pneumothorax, minor left sided hemothorax, pneumomediastinum and massive subcutaneous emphysema (Figure 2, Figure 3 and Figure 4).

Emergency surgery was performed for lung herniation. Under general anesthesia, with double-lumen intubation and single lung ventilation, the patient was positioned in dorsal decubitus position. Intraoperatively, the intercostal lung herniation was found between the second and third left ribs. The thick hernia sack that was formed of the parietal pleura was opened, the lung fell in the pleural cavity. Light adhesions bands were present in the immediate proximity

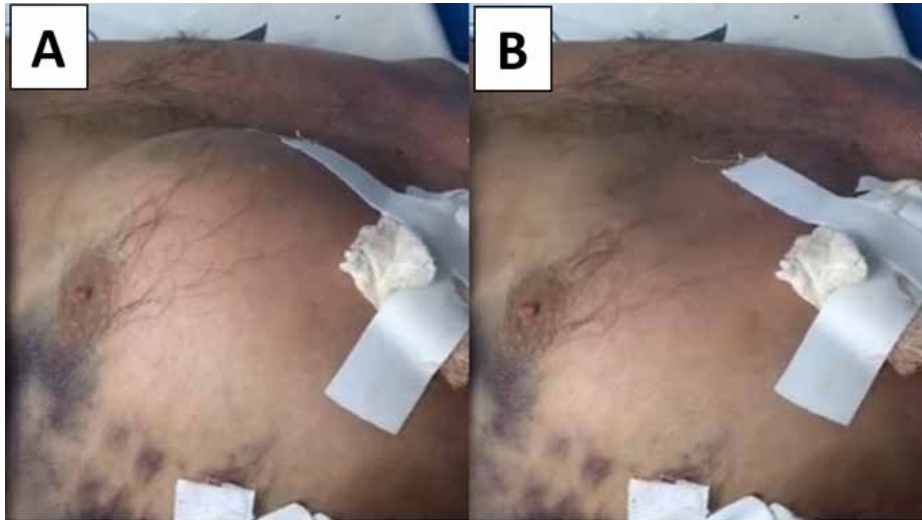

Figure 1. (A) and (B) Paradoxical movement as seen at the time of patient admission.

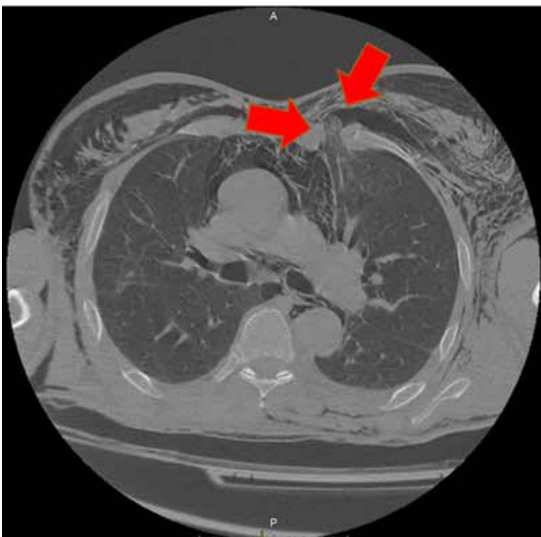


Figure 2. Axial view of chest computed tomography image that shows the left lung that herniates through a chest wall defect (red arrows).

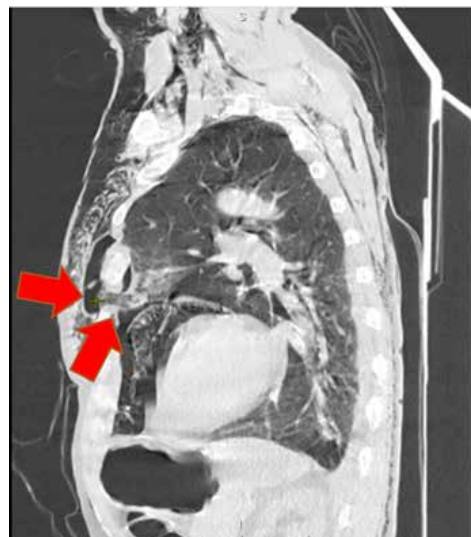

Figure 3. Sagittal view of chest computed tomography image that shows the left lung that herniates through a chest wall defect (red arrows).

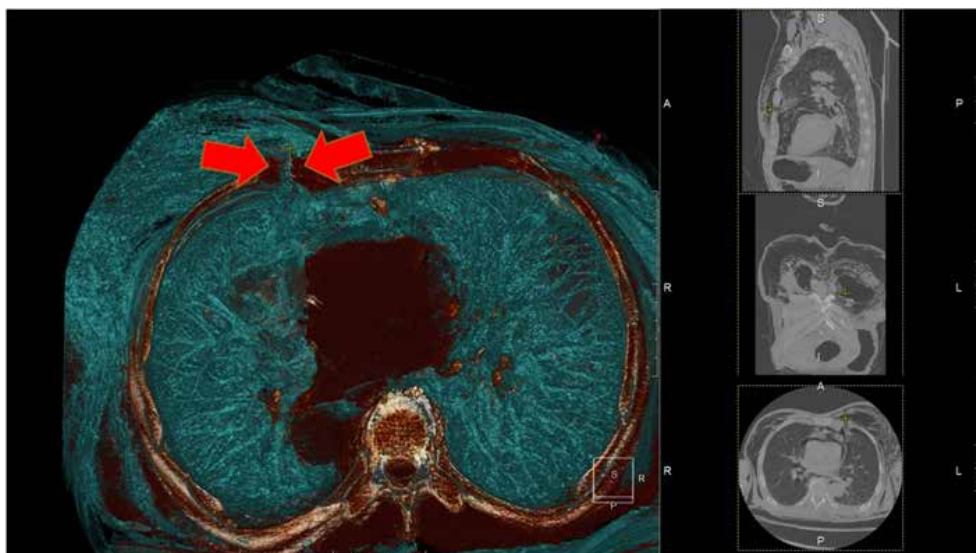


Figure 4. Preoperative three dimensional computed tomography shows the left lung protruding into the thoracic wall defect (red arrows).

of the defect and were divided by cautery. A 28-French chest tube was placed in the left "Safe triangle". Surgical closure was performed by fixation of second and third ribs by monofilament suture and using local soft tissues. The patient was extubated, after surgery, in the operative room, the chest tube was removed on the third postoperative day. Hospital stay was uneventful, and the patient was discharged in stable clinical condition, ten days after the operation. A chest radiograph, obtained in the outpatient department, one month after surgery showed clear lung fields and resolution of subcutaneous emphysema. There was no recurrence during the three months of follow-up.

Discussions

The first report of lung herniation was made by Roland in 1499 [4]. There are two types of lung herniation: congenital or acquired and 80% of lung hernias are acquired [5]. Congenital herniation is caused by debilitation of the endothoracic fascia [5] and acquired herniations usually develops as a result of trauma, thoracic surgical interventions or spontaneously [6]. Generally, acquired lung herniation is related to trauma, but can also be spontaneous, or caused by local pathologic conditions [7]. If lung herniation is clinically suspected it is confirmed by chest radiography or Computed Tomography (CT) [5]. There is no clearly defined tactic regarding the management of lung herniation. Treatment can be conservative but, in most cases, surgical repair is needed [8]. Conservative treatment consists of compression with pads, corsets, treating the underlying cause and weight loss [7]. It should be mentioned that chest wall compression is associated with a limited thoracic wall motion, pulmonary compliance reduction, and the increased risk of atelectasis and infection [3]. The decision on surgery is based upon the size of the hernia, the symptoms, the risk organs or tissue incarceration, and the patient's comorbidities [8, 9]. Surgical technique varies, and includes direct closure of the defect, and closure with a mesh or muscle flaps [3]. The most commonly used surgical method, after adhesion bands

section or resecting the incarcerated lung parenchyma, is pericostal fixation of the adjacent ribs with absorbable sutures, via thoracotomy [3]. For small defects, pericostal fixation is useful, but larger defects require a larger chest wall reconstruction, using surrounding tissues or synthetic materials [8]. Plastic surgical interventions, such as muscle flaps or *fascia lata* are usually used in large thoracic wall defects. The nonabsorbable (polypropylene and expanded polytetrafluoroethylene) and absorbable (polyglactin; Viracyl) meshes can be used in the repair of lung herniation. However, there were reports of complication occurrence because of meshes, such as the formation of fistulas, seromas and infection [3]. In most cases lung hernia repairs are performed via thoracotomy or a "mini"-thoracotomy, but there are also several reports of successful repair using Video Assisted Thoracic Surgery (VATS) approach [9-12].

Conclusions

It is important to maintain a high level of medical team and patient education to help with early diagnosis of such cases. Conservative management is applicable in some cases but close patient supervision is mandatory and surgical treatment should be applied on first signs of aggravating clinical signs. Surgical repair is mandatory to prevent further complications. Patients that suffer or have a history of blunt thoracic trauma must be assessed for possible lung herniation. Also a differential diagnosis of lung herniation for the patients with blunt traumatic chest injuries and rib fractures should be made as this may affect surgical management.

Consent

Written informed consent was obtained from the patient for publication of this case report and accompanying images.

Ethical approval

Ethical approval has been exempted by our institution.

Bibliography

1. Sulaiman A, Cottin V, De Souza Neto EP, et al. Cough-induced intercostal lung herniation requiring surgery: Report of a case. *Surg Today*. 2006;36(11):978-980. doi:10.1007/s00595-006-3284-8
2. Lykissas MG, Zikos N, Kazakos N, Giasis K, Paparounas K. Post-traumatic intercostal lung hernia. *Injury Extra*. 2006;37(7):258-60. doi:10.1016/j.injury.2005.12.027
3. Fackeldey V, Junge K, Hinck D, et al. Repair of intercostal pulmonary herniation. *Hernia*. 2003;7(4):215-217. doi:10.1007/s10029-003-0135-z
4. Ross RT, Burnett CM. Atraumatic lung hernia. *Ann Thorac Surg*. 1999;67(5):1496-1497. doi:10.1016/s0003-4975(99)00225-8
5. Weissberg D. Lung hernia - a review. *Adv Clin Exp Med*. 2013;22(5):611-613.
6. Athanassiadi K, Bagaev E, Simon A, Haverich A. Lung herniation: a rare complication in minimally invasive cardiothoracic surgery. *Eur J Cardiothorac Surg*. 2008;33(5):774-776. doi:10.1016/j.ejcts.2008.01.027
7. Forty J, Wells FC. Traumatic intercostal pulmonary hernia. *Ann Thorac Surg*. 1990;49(4):670-671. doi:10.1016/0003-4975(90)90325-z
8. Kara HV, Javidfar J, D'Amico TA. Spontaneous herniation of the lung and diaphragm treated with surgical repair. *Ann Thorac Surg*. 2015;99(5):1821-1823. doi:10.1016/j.athoracsur.2014.06.105
9. Reardon MJ, Fabré J, Reardon PR, Baldwin JC. Video-assisted repair of a traumatic intercostal pulmonary hernia. *Ann Thorac Surg*. 1998;65(4):1155-1157. doi:10.1016/s0003-4975(98)00035-6
10. Hebra A, Cina R, Streck C. Video-assisted thoracoscopic repair of a lung hernia in a child. *J Laparoendosc Adv Surg Tech A*. 2011;21(8):763-765. doi:10.1089/lap.2011.0147

11. Khalil MW, Masala N, Waller DA, Cardillo G. Surgical repair of post-traumatic lung hernia using a video-assisted open technique. *Interact Cardiovasc Thorac Surg.* 2008;7(3):506-507. doi:10.1510/icvts.2007.168658
 12. Fison V, Portale G, Frigo F, Migliorini G. Thoracoscopic repair of lung herniation following minimally invasive cardiothoracic surgery. *Chir Ital.* 2009;61(2):261-263.
-

Received – 16.01.2023, accepted for publication – 07.04.2023

Corresponding author: Serghei Guțu, e-mail: gutsu.sergiu.91@gmail.com

Conflict of interest Statement: The authors reports no conflicts of interest in this work.

Funding Statement: The authors reports no financial support.

Citation: Guțu S, Burlacu I, Maxim I. Lung herniation following blunt thoracic trauma: case report. *Arta Medica.* 2023;86(1):54-57.